



Kasuistika | Case report

Left ventricular perforation by a guidewire crossing a stenotic calcific aortic valve

Şenol Demircan, Hakan Altay

Department of Cardiology, Baskent University, Faculty of Medicine, Ankara, Turkey

ARTICLE INFO

Article history:

Received: 8 May 2012

Accepted: 30 May 2012

Available online: 14 June 2012

ABSTRACT

With the availability of better technology in catheterization techniques, perforation of myocardium during cardiac catheterization is a rare event. We report, a 65-year old male who developed this potentially life threatening complication, after several attempts were made to cross a heavily stenotic aortic valve. With this case presentation, we aim to call attention to this complication which we think will occur more frequently in the era of percutaneous aortic valve replacement.

Keywords:

Aortic stenosis

Diagnostic catheterization

Left ventricle perforation

© 2012, ČKS. Published by Elsevier Urban and Partner Sp. z o.o. All rights reserved.

Introduction

Retrograde passage of a severely stenotic valve, with the purpose to measure invasively the gradient across the aortic valve carries risks of valve perforation and distal embolization of calcific material [1]. Generally, echocardiography is enough for assessment of severity of aortic stenosis and cardiac catheterization is not recommended when echocardiography yields conclusive results [2]. We present a patient who suffered a perforation of left ventricle during the catheterization and needed surgery at the end.

Case

An 65-year old male, with history of hypertension, presented to our hospital with exertional angina and dyspnea.

The cardiovascular examination revealed systolic ejection murmur at the right upper sternal border that radiates to the neck. The electrocardiography demonstrated left ventricular hypertrophy. The laboratory test results were within normal limits. A transthoracic echocardiogram showed mild aortic regurgitation and moderate aortic stenosis with maximum and mean gradient, 50 mmHg and 24.8 mmHg, respectively. The aortic valve was tricuspid and severely calcific. There was normal ventricular function with no wall motion abnormality. He couldn't complete the treadmill exercise test because of fatigue. Owing to suspicion of coronary artery disease, a left sided cardiac catheterization was performed. The coronary arteries were normal. Since there is a discrepancy between clinical and echocardiographic findings regarding severity of aortic stenosis and marked aortic calcification, evaluation of aortic valve via cardiac catheterization was planned. Several unsuccessful attempts were made to cross the heavily calcified aortic valve via a pigtail catheter.

Address: Şenol Demircan, MD, Department of Cardiology, Baskent University, Faculty of Medicine, Dadaloglu Mah. 6 sk. No 9, 01250, Yuregir, Adana, Turkey, e-mail: senoldemircan2@hotmail.com

DOI: 10.1016/j.crvasa.2012.05.016

Please cite this article as: S. Demircan, H. Altay, Left ventricular perforation by a guide wire crossing a stenotic calcific aortic valve, *Cor et Vasa* 55 (2013) e76–e77 as published in the online version of *Cor et Vasa* available at <http://www.sciencedirect.com/science/article/pii/S0010865012000689>

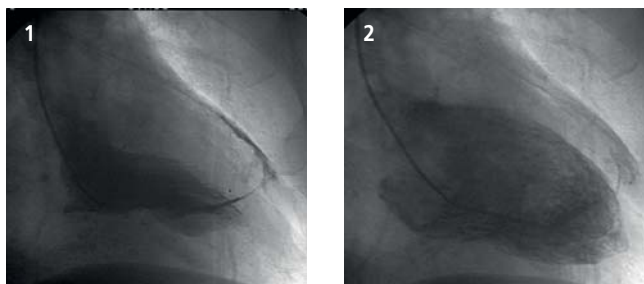


Fig. 1 – LV angiogram in RAO 45 view showing pigtail catheter and contrast material in pericardial space while the ventricle is in systolic phase.

Fig. 2 – LV angiogram in RAO 45 view showing contrast material in pericardial space while the ventricle is in diastolic phase.

ter over a j tipped guidewire. At the end the valve was crossed with a right judkins catheter (JR4) using a straight tip guide wire and then exchanged with a pigtail catheter over a j tipped guidewire. The left ventricular (LV) pressure and end diastolic pressure were 160 and 22 mmHg, respectively, and central aortic pressure recorded previously was 120/60/80 mmHg. When the LV angiogram was performed, a part of the pigtail was seen lying in the pericardial space having perforated the LV apex. A part of the contrast material entered the pericardial space (Fig. 1,2) (video) and soon cardiac tamponade ensued with marked hypotension. An immediate echocardiogram revealed an apicolateral pericardial fluid collection which is 10 mm at its maximum width. An immediate pericardiocentesis was done with a pigtail catheter which was left in the pericardial space while the patient was transferred to the operation room. He underwent operation in which the defect in the LV wall was repaired.

Supplementary material related to this article can be found online at doi:10.1016/j.crvasa.2012.05.016.

Discussion

Accidental perforation of a left ventricle with a guidewire after retrograde crossing of a calcified aortic valve during catheterization is rarely reported in the literature. Although we do not generally do cardiac catheterization

for assessment of severity of aortic stenosis, in this situation, we found it mandatory to evaluate the severity of aortic stenosis via catheter because clinical and echocardiographic data disparated.

Recognition of this complication should be early since it is a life threatening complication which can lead to cardiac tamponade and shock in seconds. Friedrich et al. discussed the diagnosis and management of this complication [3]. Most of the time pericardiocentesis is sufficient and surgical treatment is not necessary. Swinkels et al. reported a case in whom conservative treatment was successful [4]. In our case, despite successful pericardiocentesis was immediately done, surgical treatment was needed. In the era of percutaneous aortic valve replacement, it is likely that the number of valve crossings will increase and this complication will occur more frequently in patients with calcific aortic stenosis.

Appendix A – Supporting information

Supplementary data associated with this article can be found in the online version at <http://dx.doi.org/10.1016/j.crvasa.2012.05.016>.

References

- [1] H. Omran, H. Schmidt, M. Hackenbroch, et al., Silent and apparent cerebral embolism after retrograde catheterisation of the aortic valve in valvular stenosis: a prospective, randomised study, *Lancet* 361 (2003) 1241–1246.
- [2] R.O. Bonow, B.A. Carabello, K. Chatterjee, et al., American College of Cardiology/American Heart Association Task Force on Practice Guidelines, 2008 focused update incorporated into the ACC/AHA 2006 guidelines for the management of patients with valvular heart disease: a report of the American College of Cardiology/American Heart Association Task Force on Practice Guidelines (Writing Committee to revise the 1998 guidelines for the management of patients with valvular heart disease). Endorsed by the Society of Cardiovascular Anesthesiologists, Society for Cardiovascular Angiography and Interventions, and Society of Thoracic Surgeons, *Journal of the American College of Cardiology* 52 (2008) 1–142.
- [3] S.P. Friedrich, A.D. Berman, D.S. Baim, D.J. Diver, Myocardial perforation in the cardiac catheterization laboratory: incidence, presentation, diagnosis, and management, *Catheterization and Cardiovascular Diagnosis* 32 (1994) 99–107.
- [4] B.M. Swinkels, T.J. ten Cate, N.A. Haenen, et al., Myocardial perforation by a guidewire crossing a stenotic aortic valve during cardiac catheterization, *International Journal of Cardiology* 39 (2010) 21–23.