



ELSEVIER

ScienceDirect

journal homepage: www.elsevier.com/locate/crvasa

Kasuistika | Case report

Iatrogenic life-threatening condition in a patient with multiple rare disorders

Martyna Zaleska^a, Olga Możeńska^a, Mariola Laszuk^a, Piotr Suwalski^{b,c},
Dariusz Artur Kosior^d

^a Department of Cardiology and Hypertension, Central Research Hospital, The Ministry of the Interior, Wołoska 137, 02-507 Warsaw, Mazovia, Poland

^b Department of Cardiac Surgery, Central Research Hospital, The Ministry of the Interior, Wołoska 137, 02-507 Warsaw, Mazovia, Poland

^c Faculty of Health Sciences, Pulaski University, Malczewskiego 29, 26-600 Radom, Mazovia, Poland

^d Department of Applied Physiology, Mossakowski Medical Research Centre, Polish Academy of Sciences, Pawińskiego 5, 02-106 Warsaw, Mazovia, Poland

ARTICLE INFO

Article history:

Received: 28. 1. 2017

Received in revised form: 19. 6. 2017

Accepted: 21. 6. 2017

Available online: 23. 7. 2017

Klíčová slova:

Andersenův–Tawilův syndrom

Antikoagulační léčba

Infekční endokarditida

Multiorganové selhání

Náhrada chlopně

Syndrom dlouhého intervalu QT

Vrozené onemocnění

Keywords:

Andersen–Tawil syndrome

Anticoagulant treatment

Congenital disease

Infectious endocarditis

Long QT syndrome

Multi-organ failure

Valve replacement

SOUHRN

Andersenův–Tawilův syndrom (7. forma syndromu dlouhého intervalu QT) je vzácné dědičné onemocnění charakterizované periodickou paralýzou, dlouhým intervalem QT, komorovými arytmiemi a abnormalitami kostry.

Dvaapadesátiletá žena s anamnézou syndromu dlouhého intervalu QT, implantace kardioverteru-defibrilátoru (v rámci sekundární prevence srdeční zástavy) a systémové vaskulitidy, byla hospitalizována pro elektrickou bouři vyvolanou endokarditidou. Krátce po propuštění byla pacientka znovu hospitalizována pro multiorganové selhání, velmi pravděpodobně vyvolané vysazením steroidů a VKA. K podezření na Andersenův–Tawilův syndrom vedly lékaře její charakteristické dysmorfny rysy.

U pacientů s jednou vzácnou poruchou nelze zůstat u jedné diagnózy; přitom je třeba zajistit další důkladné ambulantní kontroly.

© 2017, ČKS. Published by Elsevier Sp. z o.o. All rights reserved.

ABSTRACT

Andersen–Tawil syndrome (long QT syndrome 7) is a rare inherited disorder, characterized by periodic paralysis, long QT, ventricular arrhythmias and skeletal abnormalities.

A 52-year-old female with a history of long QT syndrome, ICD implantation (secondary prevention of cardiac arrest) and systemic vasculitis was admitted due to an electrical storm caused by endocarditis. She was admitted again short after discharge due to multi-organ failure, which was caused probably by withdrawal of steroids and VKA. Characteristic dysmorphic features resulted in Andersen–Tawil syndrome suspicion.

If patients have one rare disorder they should not be excluded from further diagnostics, and very detailed outpatient care.

Address: Dariusz Artur Kosior, MD, PhD, FACC, FESC, Wołoska 137, 02-507 Warsaw, Poland, e-mail: dkosior13@gmail.com

DOI: 10.1016/j.crvasa.2017.06.010

Introduction

Congenital long QT syndrome (LQTS) is a genetic disorder characterized by QT interval prolongation due to gene mutations encoding cardiac ion channel proteins. It predisposes to sudden cardiac death in the mechanism of ventricular tachycardia (VT, mostly *torsade de pointes*) or ventricular fibrillation (VF) [1]. Diagnosis of LQTS is established based on medical history, clinical outcomes and electrocardiography (ECG). Also, genetic tests can confirm the right diagnosis [1].

One of the LQTS is LQTS7, named also Andersen–Tawil syndrome (ATS). This syndrome is caused by *KCNJ2*-gene mutation, coding the potassium (K) channel I_{K1} . Features characteristic for ATS include periodic paralysis, dysmorphic features and heart rhythm disorders (prolonged QT interval and ventricular arrhythmias) [2].

Case report

A fifty-two-year old white female patient, diagnosed with congenital LQTS at the age of 47 years, just after successfully resuscitated pre-hospital cardiac arrest followed by cardioverter defibrillator (ICD) implantation, with medical history of superficial left arm and brachiocephalic vein thrombosis, epilepsy and anti-PR3 ANCA antibodies vasculitis, was admitted to our Department of Cardiology due to electrical storm (with the most probable cause – electrode damage during the course of endocarditis). Ventricular electrode dysfunction requiring immediate replacement was revealed during ICD control. Implanted cardioverter defibrillator, with all electrodes and the device itself, was removed, a smear from the tip of the ventricular electrode was performed and the bacterial cause of the electrical storm was proven. Additional microbiology results showed the occurrence of methicillin-resistant *Staphylococcus epidermidis*, gentamicin and vancomycin sensitive. Additionally, three blood cultures were collected; each of them proved positive. Transesophageal echocardiography (TOE) demonstrated infective endocarditis with vegetation on both: the atrial electrode (Fig. 1B) and mitral valve (MV) (Fig. 1A) leading to severe regurgitation.

Antibiogram guided therapy with gentamicin and vancomycin was implemented and conducted for 6 weeks. Due to systemic vasculitis, concomitant therapy with azathioprine and corticosteroids was required as well as antithrombotic treatment due to autoimmune disease, history of thrombosis and temporal immobilization. The-rapy with enoxaparin resulted in thrombocytopenia with platelets count 20,000/ μ L 12 hours after low-molecular heparin administration followed by diagnosis of heparin-induced thrombocytopenia (HIT). After the withdrawal of enoxaparin and azathioprine and elevation of steroids doses, the platelet level increased to 50,000/ μ L.

The patient was transferred to the Department of Cardiothoracic Surgery for MV replacement and tricuspid valve (TV) repair. During cardiopulmonary bypass surgery, biological prosthesis and tricuspid annulus were implanted. During the post-operative period TTE was performed showing that the TV was tight and no dysfunction of MV was observed. Twenty days after surgery the patient was discharged. The patient required long-term antithrombotic treatment due to biological prosthesis, with the following risk factors: history of venous thromboembolism and hypercoagulation – systemic vasculitis. Vitamin K antagonist (VKA) therapy was initiated with the INR ranging between 2.5 and 3.0.

Twenty-six days after discharge the patient was admitted again to the Department of Cardiology in very severe general condition, close to circulation and respiratory collapse. Clinical condition suggested severe, most likely infective, exacerbation of congestive heart failure, with multi-organ failure features, such as acute renal and hepatic failure. The patient reported nausea and emesis for the past several days, in addition to an increasing cough for approximately 3 weeks, persistent elevated body temperature, dyspnea (NYHA class IV), as well as pain in the right calf (including its contusion and edema). Laboratory data included increased alanine and aspartate aminotransferases (3291 IU/L and 7186 IU/L respectively), decreased estimated glomerular filtration rate (30 mL/min/1.73 m²) as well as increased creatinine and C-reactive protein (CRP) levels (1.8 mg/dL and 44.6 mg/L respectively). Additionally, D-dimer was increased up to 52,605 pg/mL, platelets were below normal range

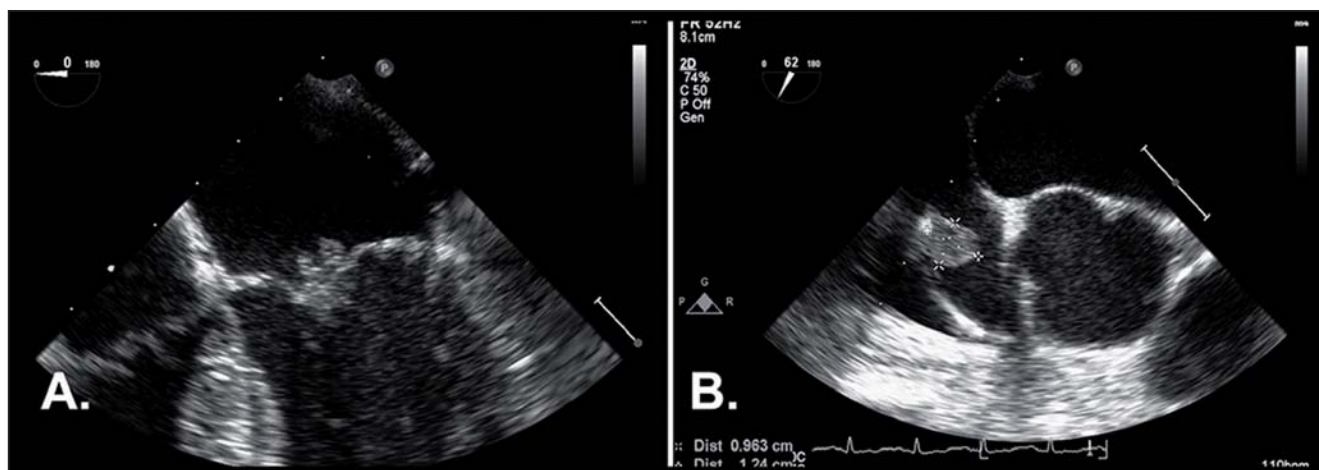


Fig. 1 – (A) Vegetation on mitral valve; (B) vegetation on atrial electrode's tip.

($100 \times 10^3/\mu\text{L}$), NT-proBNP value was elevated up to 23,265 $\mu\text{g/L}$ and INR was 1.92. After administration of enoxaparin in the ER the platelet count at admission was 55,000/ μL .

Intensive i.v. infusion of furosemide, followed by fractionated doses and oral therapy was introduced. Gradual therapy with metoprolol, which due to congenital LQTS, the patient received permanently, short-acting angiotensin-converting enzyme inhibitor and spironolactone were implemented. Medications doses were adjusted to the blood pressure and heart rate. Increased CRP level was observed; therefore, blood cultures were collected and empirical therapy with piperacillin with tazobactam was initiated. We began with 4.5 g i.v. every 12 h. Then the antibiotic dosage was adjusted to patient's renal parameters. We up-titrated it up to 4.5 g every 8 h, followed by 4.5 g 4-times per day. Urine cultures showed *Escherichia coli* and *Klebsiella pneumoniae* presence. Urine cultures collected after antibiotic therapy were negative. Due to the increased level of D-dimer and diagnosis of right crus deep vein thrombosis intensification of antithrombotic treatment was required. Due to history of HIT treatment with VKA bridged by fondaparinux was gradually initiated. Due to the history of anti-PR3 ANCA antibody vasculitis the patient was treated with prednisone (10 mg daily).

Since the 4th day of hospitalization we observed gradual improvement of both the clinical condition and laboratory data. Due to the stabilization of the clinical condition and lack of an active infective process another ICD was successfully implanted.

On the 25th day the patient was discharged in good general condition. After one year, the patient's clinical condition is stable, being fully functional (NYHA II).

Discussion

An indication of LQTS is the prolongation of QTc to more than 460 ms or 450 ms amongst women and men, respectively [1]. T-wave morphology and changeability and presence of the U-wave with high amplitude also have diagnostic significance [3]. Additionally, significant is the history of torsade de pointes, sometimes transforming into VF. Clinical symptoms of congenital LQTS include syncope, cardiac arrest and family history of syncope or death at young age. Also, characteristic dysmorphic features, such as hypertelorism, micrognathia, low-set ears high arched or cleft palate, short stature, scoliosis, syndactyly and clinodactyly are described in patients with LQTS [4]. In case of ATS-patients ventricular bigeminy, ventricular arrhythmias, polymorphic or two-way VT insertions are also common. Distinct U-wave is characteristic of this syndrome [2,3].

In our patient during 24-hour Holter ECG performed after the 1st cardiac arrest we assessed QT intervals periodically up to 600 ms at night, 182 ventricular extrasystoles with 1 ventricular couple and high T deflections, which resulted in the diagnosis of LQTS. Due to the characteristic dysmorphic features: micrognathia, low-set ears, hypertelorism, microcephaly, suspicion of ATS was raised. It was confirmed by means of genetic tests (spe-

cific potassium-channel gene mutation on chromosome 17) [4]. Patients with congenital LQTS with symptoms unresponsive to β -blocker therapy or pause-dependent ventricular arrhythmia require ICD implantation [5]. In this patient, the ICD was implanted as a secondary prevention of cardiac arrest. The cardiac-device related infective endocarditis (CDRIE) with blood stream infection, which occurred in our patient, is a complication estimated at 1.14 per 1000 device-years [6]. Cardiac-device related endocarditis involves high in-hospital mortality – 14.7% [7]. Some authors reported that coexisting valve infection was found in 37.3% of patients with CDRIE [6]. In this particular case MV replacement and TV repair was performed.

Heparin induced thrombocytopenia is a rare side effect following treatment with heparin. Predisposing factors to develop HIT include heart failure, coronary artery disease, hypertension, autoimmune disease, gout, active infection and haemodialysis [8], most of which were present in our patient. Detailed medical history revealed that the general practitioner withdrew VKA a couple of weeks prior to chronic heart failure (CHF) exacerbation. Most likely, due to liable INR results, therapy with acetylsalicylic acid was initiated, which proved inefficient considering thromboembolic episodes prevention (history of superficial vein thrombosis, biological prosthesis, autoimmune disease). Detailed medical history also revealed the withdrawal of oral steroids due to the patient's misunderstanding of the therapeutic regimen. The above-mentioned could have been the cause of recurrent deep vein thrombosis. Additional CHF exacerbation and multi-organ failure led to life-threatening condition.

Conclusions

It is worth mentioning that despite multiple rare disorders diagnosed in our patient (LQTS, ATS, HIT, systemic anti-PR3 ANCA-vasculitis), neither of hospitalizations were caused by them. The cause of both hospitalizations included interventional complications, which were aimed at preventing symptoms. It is important to keep in mind that not rare disorders, but common diseases (IE, CHF exacerbation, deep vein thrombosis) complicating rare disorders are difficult to treat and may be lethal. In conclusion, if patients have one rare disorder, they should not be excluded from further diagnostics, and very detailed, even if sometimes challenging, outpatient care.

Conflict of interest

The authors declare that they have no conflict of interest.

Funding body

None.

Ethical statement

Authors state that the research was conducted according to ethical standards.

Informed consent

I declare, on behalf of all authors, that informed consent was obtained from the patient participating in this study.

Appendix A. Supplementary data

Supplementary data associated with this article can be found, in the online version, at doi:10.1016/j.crvasa.2017.06.010.

References

- [1] P.J. Schwartz, A.J. Moss, G.M. Vincent, et al., Diagnostic criteria for the long QT syndrome. An update, *Circulation* 88 (1993) 782–784.
- [2] M. Tristani-Firouzi, J.L. Jensen, M.R. Donaldson, et al., Functional and clinical characterization of KCNJ2 mutations associated with LQT7 (Andersen syndrome), *Journal of Clinical Investigation* 110 (2002) 381–388.
- [3] L. Zhang, D.W. Benson, M. Tristani-Firouzi, et al., Electrocardiographic features in Andersen–Tawil syndrome patients with KCNJ2 mutations: characteristic T–U-wave patterns predict the KCNJ2 genotype, *Circulation* 111 (2005) 2720–2726.
- [4] M.R. Donaldson, J.L. Jensen, M. Tristani-Firouzi, et al., PIP2 binding residues of Kir2.1 are common targets of mutations causing Andersen syndrome, *Neurology* 60 (2003) 1811–1816.
- [5] M. Brignole, A. Auricchio, G. Baron-Esquivias, et al., 2013 ESC guidelines on cardiac pacing and cardiac resynchronization therapy: the Task Force on cardiac pacing and resynchronization therapy of the European Society of Cardiology (ESC). Developed in collaboration with the European Heart Rhythm Association (EHRA), *European Heart Journal* 34 (2013) 2281–2329.
- [6] D.Z. Uslan, M.R. Sohail, J.L. St Sauver, et al., Permanent pacemaker and implantable cardioverter defibrillator infection: a population-based study, *Archives of Internal Medicine* 167 (2007) 669–675.
- [7] E. Athan, V.H. Chu, P. Tattevin, et al., Clinical characteristics and outcome of infective endocarditis involving implantable cardiac devices, *Journal of the American Medical Association* 307 (2012) 1727–1735.
- [8] S. Kato, K. Takahashi, K. Ayabe, et al., Heparin-induced thrombocytopenia: analysis of risk factors in medical inpatients, *British Journal of Haematology* 154 (2011) 373–377.